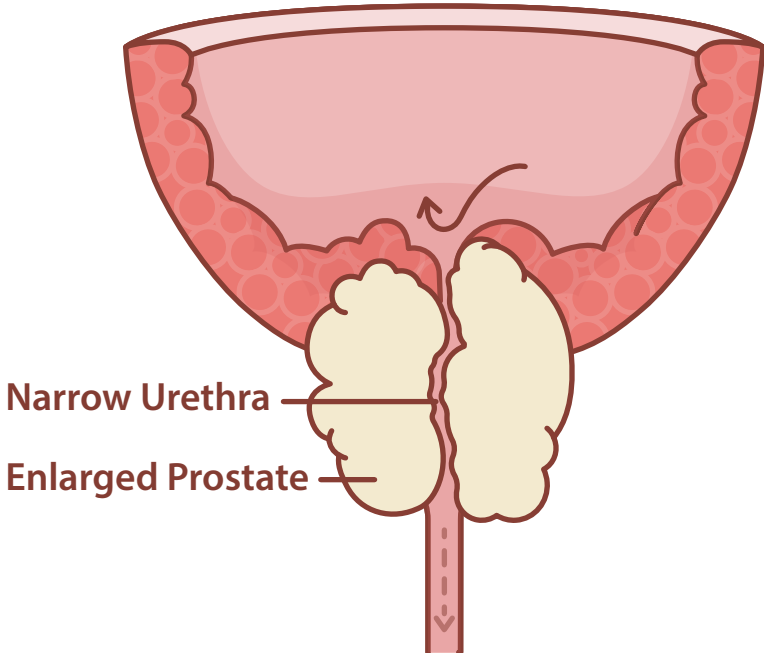
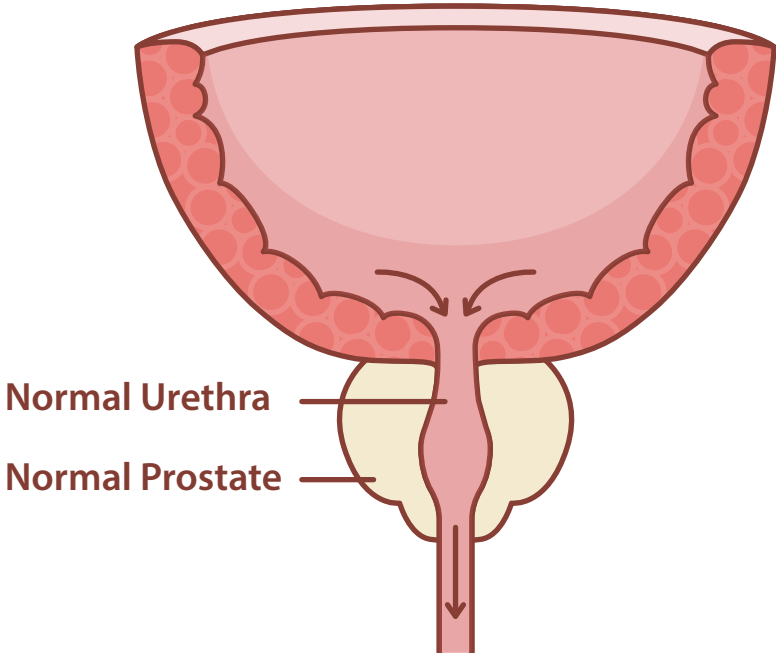
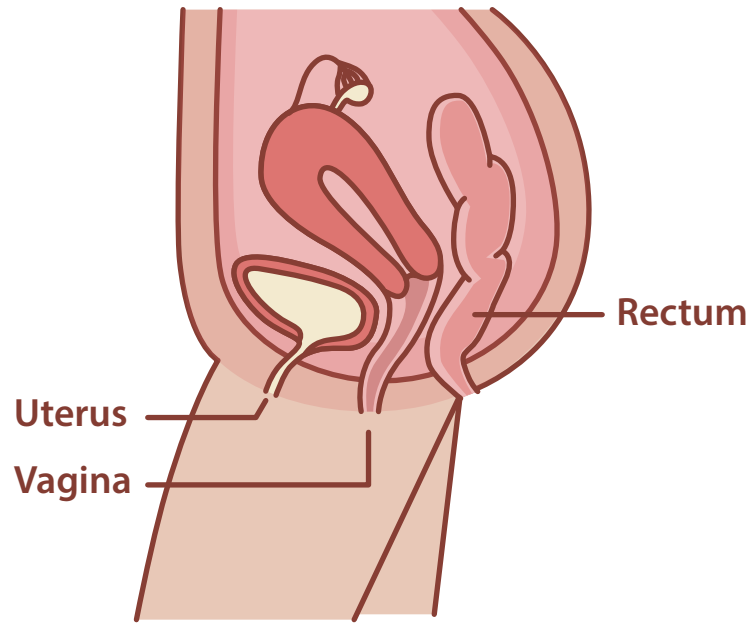


Prostate enlargement

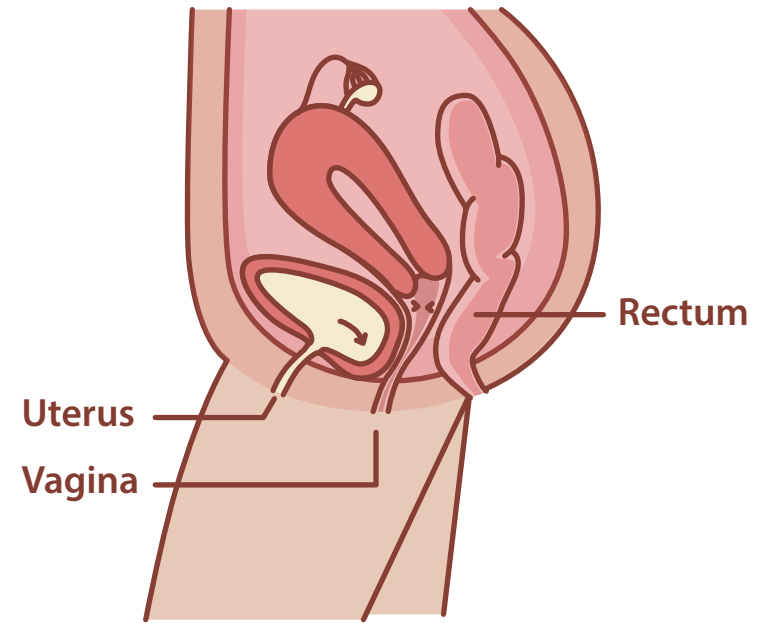


Bladder prolapse

Normal

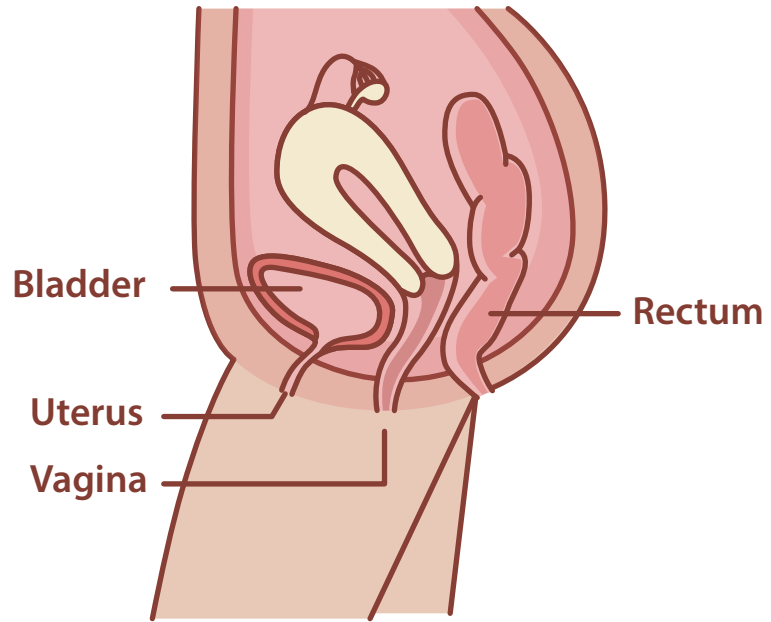


Cystocele

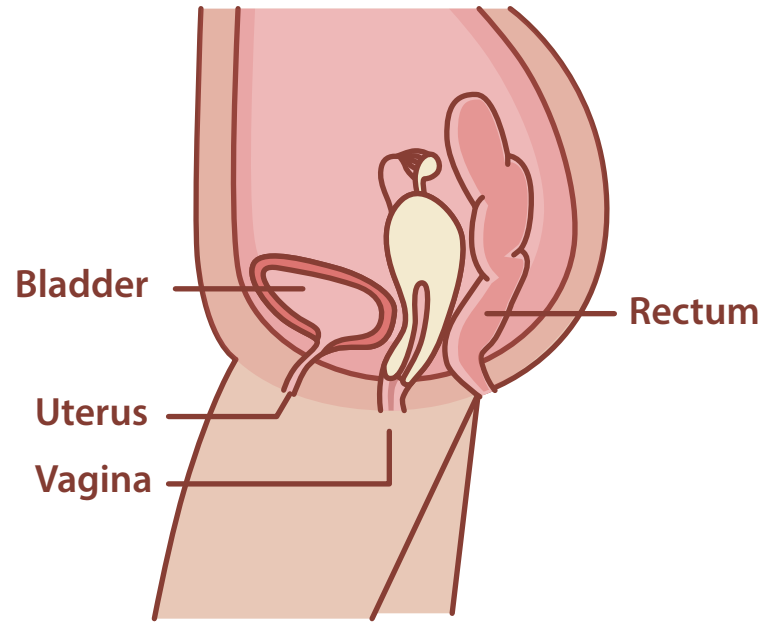


Uterine prolapse

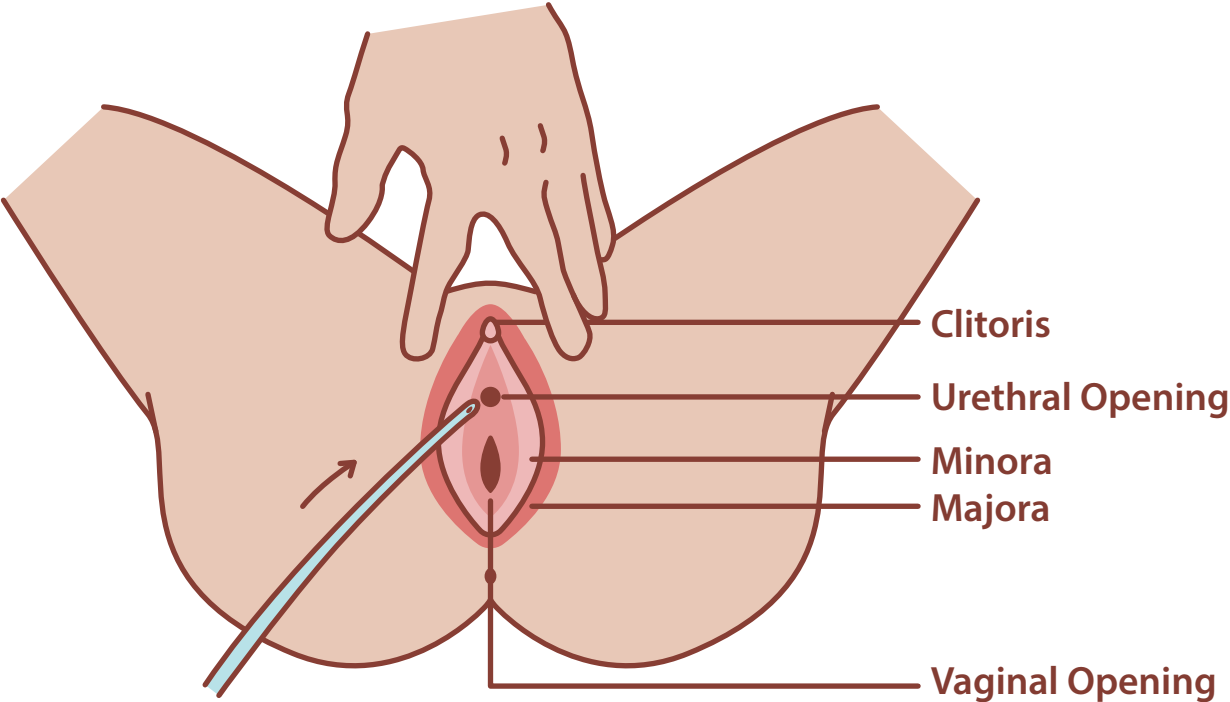
Normal



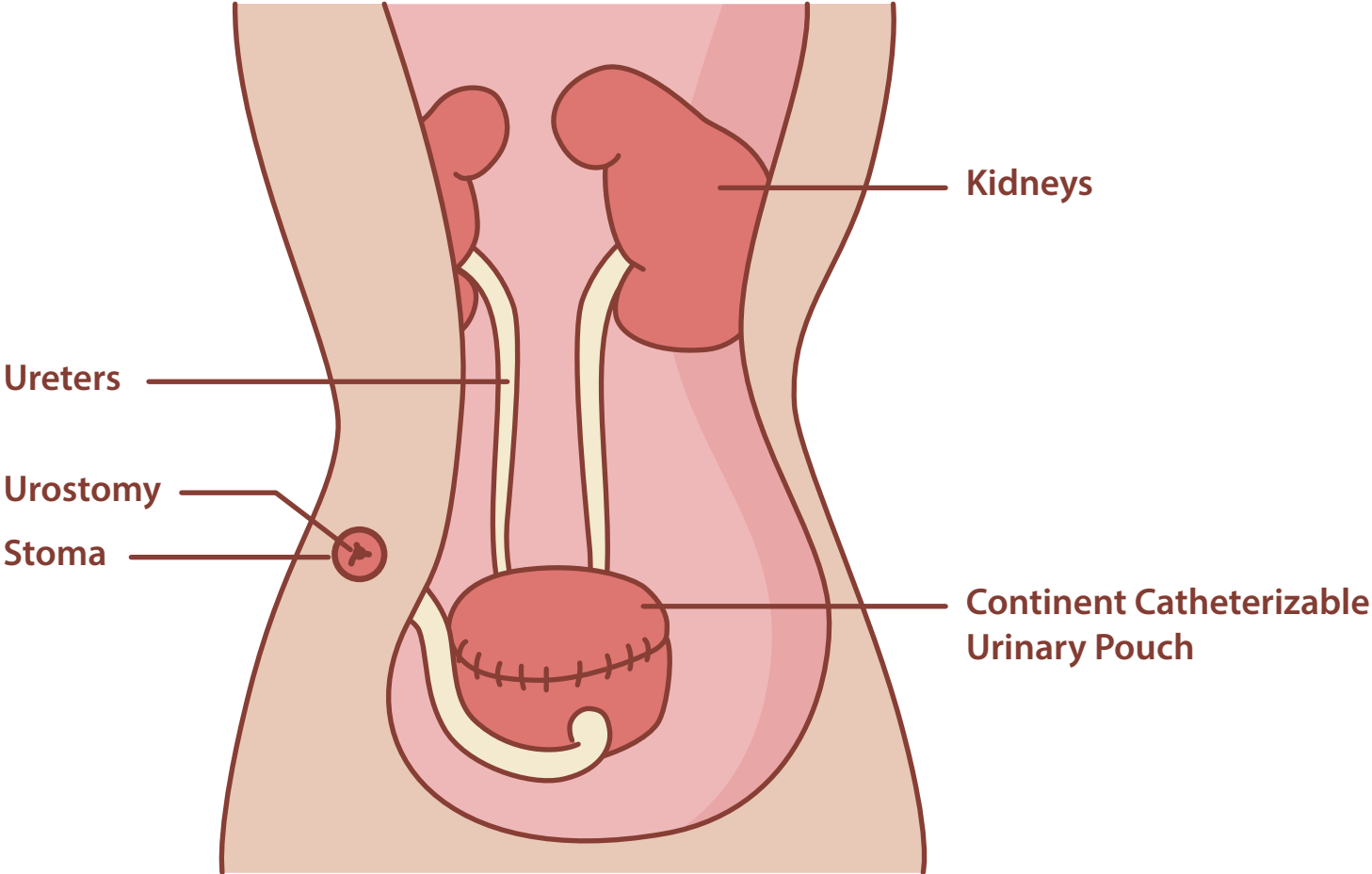
Uterine Prolapse



A woman's urethra



Indiana pouch



Prostate enlargement

